

Radiographic position of the hyoid bone in children with atypical deglutition

Almiro J. Machado Júnior and Agrício N. Crespo

Discipline of Otorhinolaryngology, School of Medical Sciences, State University of Campinas (Unicamp), Brazil

Correspondence to: Almiro J. Machado Júnior, Rua Maria Monteiro, 841 ap 11, Cambuí 13025-151 Campinas, São Paulo, Brazil. E-mail: almiro@fcm.unicamp.br

SUMMARY The persistence of childlike deglutition after the replacement of deciduous teeth is described as atypical deglutition. This condition has been attributed to sucking action without nutritive purposes, use of a feeding bottle, oral respiration, and anatomical abnormalities. Among the possible anatomical alterations, the hyoid bone, as a result of being the origin or the insertion of several muscles involved in swallowing, may have its position altered in cases of atypical deglutition. The aim of the present study was to evaluate the position of the hyoid bone using lateral telerradiographs, among patients with atypical deglutition during the stage of mixed dentition. Using cephalometric analysis on lateral telerradiographs, the distances of H–MP (hyoid to mandibular plane) and H–T (hyoid to tuber) were measured in two groups: the experimental group with atypical deglutition and the control group normal deglutition. Both groups included subjects in mixed dentition stage. Measurements from the groups were compared using Mann–Whitney *U*-test and a *P*-value <0.05 was considered as an indication of statistical significance. The average distance of the H–MP variable was 11.69 mm for the control group and 16.14 mm for the experimental group, with a statistically significant difference (*P* = 0.016). The average distance of the H–T variable was 2.26 mm for the control group and –5.89 mm for the experimental group, with significant difference (*P* < 0.001). There was no correlation among the variables studied. Cephalometric analysis of the H–MP distance revealed a mean difference of approximately 5 mm between the two groups, and the difference was more than 7 mm for H–T distance. Distances of H–MP and H–T based on radiographic measurements were greater in individuals with atypical deglutition than in control group and there was no correlation between these two parameters.

Introduction

Under normal neurological conditions, respiration, sucking, and deglutition functions are established at birth, in order to maintain extrauterine life. At the first occasion when neonates meet mother's breast, they should be capable of sucking and swallowing. At this stage of development, the tongue has a large volume, occupies the entire oral cavity, and can perform postero-anterior movements within the oral cavity (Peng *et al.*, 2003; Graber *et al.*, 1985). With the eruption of the first deciduous teeth and the physiological advancing of the mandible, the consistency of children's diets needs to be gradually increased. Thus, sucking is replaced by an impulse to bite and, later on, to chew. Childlike deglutition, with the tongue occupying the entire intraoral space in association with contraction of the perioral musculature, evolves into mature deglutition by the start of the mixed dentition stage (Peng *et al.*, 2003, 2004).

Basically, three swallowing patterns have been described: visceral, somatic, and inconstant. Visceral swallowing is that which exists at birth and is also termed 'infantile swallowing'. In neonates, the tongue is relatively large and located in the forward suckling position for nursing. The tongue lies between the anterior gum pads and assists in the

anterior lip seal. With eruption of the incisors at approximately 6 months, the tongue position starts to retract. Over a period of 12–18 months, as proprioception causes tongue postural and functional changes, a transitional period ensues. Between 2 and 4 years, functionally balanced or mature, somatic swallowing prevails (Peng *et al.*, 2004; Ovsenik *et al.*, 2007). With the eruption of the first deciduous teeth, the suction impulse decreases and is eventually replaced by the impulse to bite and at this phase, swallowing has been called 'inconstant swallowing'. Inconstant swallowing is characterized as a pattern of swallowing during the transitional period between infantile and somatic swallowing (Graber *et al.*, 1985; Peng *et al.*, 2003).

Although swallowing is the first function to be established in the stomatognathic system, it is the last process to mature because while the bone structures are growing and dentition does not take place, the tongue cannot acquire mature posture and movement. Only when the child is around 2 years of age, a pattern of transitory (inconstant) swallowing to the mature pattern—called somatic swallowing—is expected, with the tongue on the limits of the dental arcade, with the soft tissues more adjusted, and the lips sealed. A visceral type of swallow can persist well after the fourth

year of life. However, it is then considered as a dysfunction or abnormality because of its association with certain malocclusions (Graber *et al.*, 1985; Peng *et al.*, 2003).

Current studies have investigated the swallowing pattern in child development and have concluded that atypical swallowing has been present in half of the children examined at age 3, has changed significantly after age 6 but has still been present in 25 per cent at age 12 (Ovsenik *et al.*, 2007). The movements of the tongue during swallowing may be clinically assessed, asking the child to swallow liquids, semi-solids, or solids or even only saliva to observe the protrusion of the tongue with the lips half-open or, if necessary, with lips opened with the fingers (forced opening method). By placing the hands on the masseters, it is possible to observe the presence or absence of contraction and to observe the ascendant movement of the hyoid bone under the thyroid cartilage. The participation of the perioral muscles is also observed, as well as whether the swallowing is loud, if there is a retraction movement with the head, the presence of any signal which characterizes child swallowing (Bertolini *et al.*, 2003; Peng *et al.*, 2003, 2004; Ovsenik *et al.*, 2007).

For a variety of reasons that so far remain incompletely explained, 'infantile swallowing' may continue beyond the replacement of the deciduous teeth. Such deglutition is classified as atypical (Bertolini *et al.*, 2003; Peng *et al.*, 2004). Atypical deglutition has been attributed to sucking without nutritive purposes, use of feeding bottles, oral respiration, abnormalities of the central nervous system, and anatomical abnormalities (Cayley *et al.*, 2000; Cheng *et al.*, 2002; Bertolini *et al.*, 2003). However, there is no consensus regarding the aetiology of atypical deglutition. Among the likely anatomical abnormalities in cases of atypical deglutition is the position of the hyoid bone since this is the origin or insertion point of several muscles relating to deglutition. The position of this bone can be evaluated using lateral telerradiography. The stage of mixed dentition is a phase of the development in which several alterations to the stomatognathic system occur and studies have pointed out that it is during this stage that the definite transition from child swallowing (visceral) to the mature pattern (somatic) should occur (Graber *et al.*, 1985; Bertolini *et al.*, 2003; Peng *et al.*, 2003; Ovsenik *et al.*, 2007).

Studies have been conducted with the aim of establishing the standard radiographic position of the hyoid bone in relation to the cranium (Stepovich, 1965; Bibby and Preston, 1981; Rocabado, 1983; Bibby, 1984) and in cases of malocclusion (Galvão, 1983; Muto and Kanazawa, 1994; Mays *et al.*, 2009), obstructive sleep apnoea (Riley *et al.*, 1983; Jamielson *et al.*, 1986; Tsaia *et al.*, 2007), and oral respiration (Malkoc *et al.*, 2005; Ferraz *et al.*, 2007; Sheng *et al.*, 2009). However, no consensus has been reached in these studies. The aim of the present study was to evaluate the position of the hyoid bone using lateral telerradiographs, among patients with atypical deglutition during the stage of mixed dentition.

Materials and methods

The research protocol of this study received unrestricted prior approval from the Research Ethics Committee of the School of Medical Sciences, Unicamp (# 619/2005). This was an observational study in which lateral telerradiographs from children of both sexes at the phase of mixed dentition were evaluated. The whole study sample consisted of 110 telerradiographs in lateral view, from 52 female and 58 male subjects. The two groups were similar with regard to gender distribution. The mean age of the control group (normal deglutition) and the experimental group was 9.46 and 10.05 years, respectively. To define the control and experimental groups, an initial test forced opening method was conducted (Peng *et al.*, 2003, 2004) by three senior orthodontists simultaneously, defining by consensus to which group the telerradiography of the child should belong. The sample size was determined to obtain the appropriate power level.

All lateral view telerradiographs selected for the present study sized 18 × 24 cm and were obtained using the same Siemens apparatus in 1 second at 6 kVp with a focal length of 1.5 m. The examinations were performed with the patient's head in a natural position (mirror position), performed by the same examiner. Using the selected lateral telerradiographs, cephalometric examination was performed in a darkened room with a negatoscope. An acetate sheet was laid over the telerradiograph and the following anatomoradiographic points and planes were marked on the sheet:

1. H: hyoid (most antero-superior point of the body of the hyoid bone),
2. MP: mandibular plane (line from the midpoint of the mandibular angle to the lowest point on the outline of the mentonian symphysis), and
3. T: tuber (line of intersection between the centre of the pterygomaxillary fissure and the posterior nasal spine).

The point H was joined using a single ruler marked in millimetres to the MP and T lines, and the distances were measured in millimetres (Figure 1). Lateral telerradiographs that did not provide a good view of the anatomical structures used in the cephalometric examination were excluded from the study sample. Patients with dental agenesis, congenital poor orofacial formation, orthodontic and/or functional orthopaedic treatment prior to the study, or doubts and imprecision regarding the diagnosis of deglutition were also excluded. A lack of unanimity among the examiners on the clinical diagnosis was also a factor of exclusion of the sample. The skeletal pattern and malocclusion of the patients were not taken into consideration in this study.

The lateral telerradiographs from the experimental group and the control group were randomly put aside and numbered sequentially. The examiner performing the manual measurements was blinded to patient data. The sequentially numbered telerradiographs were handed over to the examiner for the standardized abovementioned measurements to be

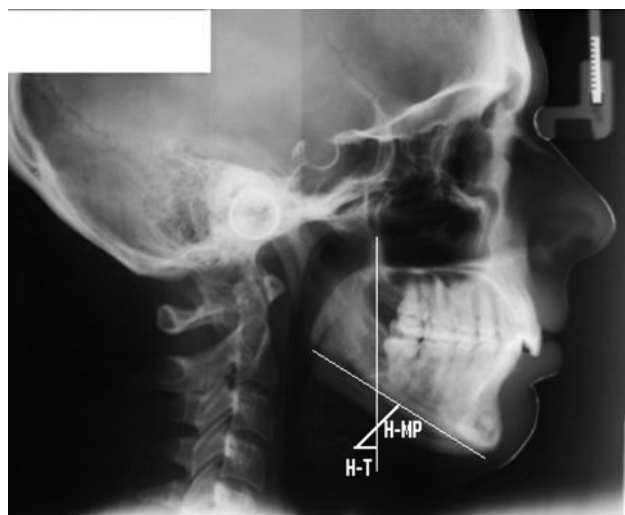


Figure 1 Cephalometric measurements: H–MP distance and H–T distance.

made, and measurement results were recorded to a data collection instrument. To minimize systematic errors, the same examiner carried out data collection of the whole sample on two occasions separated by a 20 day interval. After the collection of radiographic data, age and gender data were added, along with whether atypical deglutition was present or not. On the other hand, all appropriate measures were taken to ensure confidentiality of the subjects' personal data. Only the initials were recorded to the data collection instrument. There was no way in which persons other than the investigator would be able to identify the individual to whom each telerradiograph belonged.

To compare H–MP and H–T measurements between the two groups, Mann–Whitney *U*-test was used. Descriptive data were presented as mean, standard deviation, and range and the significance levels of the test results were estimated. To investigate a possible linear association (correlations) between variables H–MP and H–T, Spearman's correlation analysis was performed. To investigate the intra-examiner consistency, Wilcoxon test for related samples was used to detect possible differences between measurements obtained in two different occasions. The significance level used in the statistical tests was $P = 0.05$.

Results

Mann–Whitney *U*-test was used to compare the two groups with regard to cephalometric measurements. The average distance of the H–MP variable was 11.69 mm for the control group and 16.14 mm for the experimental group, with a statistically significant difference ($P = 0.016$). The average distance of the T–H variable was 2.26 mm for the control group and –5.89 mm for the experimental group, with significant difference ($P < 0.001$). There was no correlation among the variables studied.

Cephalometric analysis of the linear measurement H–MP (Table 1) showed a mean difference of approximately 5 mm between the two groups, and the difference was more than 7 mm for the variable H–T (Table 2). Both these differences were statistically significant. However, there was no correlation between these two parameters. To investigate the intra-examiner consistency, Wilcoxon test for related samples was used to detect possible differences between measurements obtained in two different occasions. However, no significant difference was found between these two measurements.

Discussion

Since deglutition is a highly complex and coordinated function, it requires activation of many anatomical structures related to the tongue. Insufficient functional stimulation of the stomatognathic system, especially the tongue, might be the main factor in the persistence of childlike deglutition (Peng *et al.*, 2003). Hyoid bone may be the most important bony structure in this process. It is of note to emphasize that it is also called 'the tongue bone'.

The oral phase of deglutition is a function that depends enormously on muscle activity. The hyoid bone is the origin or insertion point for many muscles relating to deglutition, and it is possible that its position changes in cases of atypical deglutition (Bibby, 1984). There are still concerns regarding the methods for diagnosing atypical deglutition. Prominent among the methods that have been proposed for objective diagnosis during the oral phase of deglutition is videofluoroscopy. This method has limited availability in dentistry practice, and it involves rather subjective assessments (Kikyo *et al.*, 1999; Cayley *et al.*, 2000; Peng *et al.*, 2004).

Telerradiographs are standardized extraoral images that are routinely used as an orthodontic/orthopaedic functional diagnostic tool (Malkoc *et al.*, 2005). Telerradiography has been used in a large number of studies on craniofacial growth (Pae *et al.*, 2008; Sheng *et al.*, 2009). Through this method, the spatial relationships between the cranium, vertebrae, mandible,

Table 1 Comparative analysis of the variable H–MP (millimetre).

Deglutition	<i>n</i>	Mean	SD	Minimum	Median	Maximum	<i>P</i> -value, Mann–Whitney
Normal	55	11.69	5.13	3.00	12.00	21.00	0.016
Atypical	55	16.14	4.86	7.00	16.00	27.00	

Table 2 Comparative analysis of the variable H–T (millimetre).

Deglutition	<i>n</i>	Mean	SD	Minimum	Median	Maximum	<i>P</i> -value, Mann–Whitney
Normal	55	2.26	1.79	0.00	2.00	6.00	<0.001
Atypical	55	–5.89	4.77	–16.00	–5.00	4.00	

and hyoid bone can be easily examined (Stepovich, 1965; Bibby and Preston, 1981; Rocabado, 1983; Bibby, 1984).

The position of the hyoid bone may provide useful information that would help in the diagnosis of deglutition disorders. Authors have commented on the singularity of the anatomical relations of the hyoid bone without bone articulations. This factor by itself is a potential indicator of certain individual characteristics of the importance of the diagnosis and orthodontic treatment (Bibby and Preston, 1981). The hypothesis of alteration of the position of the hyoid bone in relation to other variables in the swallowing disorder has been assessed in other studies, without detecting differences between control and experimental groups (Bibby, 1984). Our results, however, show differences between the groups.

The H-MP variable has been used in cephalometric studies about obstructive sleep apnoea and hypopnoea syndrome (OSAHS; Riley *et al.*, 1983; Tsai *et al.*, 2007). The data from these studies are similar to the results of our study because they show that in OSAHS, the hyoid bone is more distant from the mandibular plane and the same is observed in our study about atypical swallowing. This observation made us think that the hyoid bone is perhaps related to the maintenance/stabilization of the airway. We also believe that this inferior position of the hyoid bone in the group with atypical swallowing is caused by an alteration of the suprahyoid and infrahyoid muscles. Possibly hypertonia of the infrahyoid and hypotonia of the suprahyoid muscles. These altered tractions may be responsible for the altered posture of the tongue in cases of atypical swallowing (Peng *et al.*, 2003), which is more inferior than in cases of normal swallowing.

The relationship between craniofacial morphology and extrinsic factors which have an influence on the development of the face has been arousing great interest among researchers (Cayley *et al.*, 2000). Empirically, it is believed that in the cases of atypical swallowing, there is a tendency to increase the vertical dimensions of the face, although this possible alteration is not considered a cause or a consequence of atypical swallowing. If this fact were an absolute truth and if the position of the hyoid bone were dependant exclusively of the facial type, the hyoid would be closer to the mandibular plane in atypical swallowing in cases of faces with a tendency to vertical growth, a factor that was not observed in our results. Although we did not plan to correlate data of malocclusion and atypical swallowing, we believe that this possibility is real, making this possible relation deserving further studies (Graber *et al.*, 1985).

Studies have investigated the influence of atypical swallowing on the craniofacial pattern and on mandibular morphology, especially of the face vertical dimensions, but there is no consensus among researchers (Bibby, 1984; Cayley *et al.*, 2000; Cheng *et al.*, 2002). The H-T variable was originally used in this study with the intention to observe the anterior-posterior position of the hyoid bone in relation to the face. We have considered the descendant line of the pterygomaxillary fissure until the level of the hyoid

bone as mark zero; distances to its right were measured as positive values and distances to the left of the mark zero were considered negative values. Therefore, the negative value of the H-T variable found in the group with atypical swallowing refers to the more posterior position of the hyoid bone in relation to the descendant line of the pterygomaxillary fissure. A hypothesis which has already been studied is that the radiographic position of the hyoid bone is dependant of a facial type and associated to factors, such as age, obesity, breathing, apnoea (Riley *et al.*, 1983; Pae *et al.*, 2008). Our results have demonstrated that functional alterations such as atypical swallowing may also be a part of the adjunct factors, which alter the position of the hyoid bone. Although we did not intend to assess the position of the hyoid bone of the patients with atypical swallowing in different facial types, this hypothesis seems appropriate and deserves further studies.

We believe that the lower and more posterior position of the hyoid bone in the group with atypical swallowing is due to muscle alterations and unbalance, mainly in the muscles of the tongue. Swallowing is a complex and coordinated function involving a large number of muscles, notably the muscles of the tongue which are composed of intrinsic muscles (inferior and superior, transversal, and vertical longitudinal muscle fibres) and extrinsic muscles (Peng *et al.*, 2003).

The extrinsic muscles of the tongue (genioglossus, styloglossus, palatoglossus, hyoglossus, and geniohyoid) may possibly have their tonus altered. This possibility has already been observed in studies with ultrasonography (Peng *et al.*, 2003, 2004). These studies suggest that in atypical swallowing, the activity of the genioglossus muscle is increased, which would explain the lowered posture of the tongue in atypical swallowing. It also mentions that the geniohyoid and mylohyoid were adequate of the distinction of visceral swallowing. This factor may be validated by the inferior and posterior position of the hyoid bone, as our results show.

We carried out data collection over the entire sample on two occasions, in an attempt to minimize the systematic error. We evaluated whether the data collected by the same examiner at two different times might vary significantly. However, no significant difference was found between the two measurements, confirming intra-examiner consistency of the method. Although the variables are measurable, a non-parametric statistical analysis (Mann-Whitney *U*-test) was used on account of the irregular distribution of the sample's data. Since this was a retrospective study based on telerradiographic analysis, it was not possible to assess whether the measurements studied have changed after correction of the deglutition disorder.

It is a fact that the clinic test used in the definition of the type of normal or atypical swallowing has its limitations and that the final diagnosis of the type of swallowing has also been based on the experience of each examiner, assessing the involvement of the orbicular muscles in

swallowing, and other compensatory components. Perfect sealing of the oral cavity, contraction of the masseter muscle that helps the dental occlusion, necessary for swallowing was observed in normal swallowing. Lip incompetence and effort on the perioral muscles to help swallowing, and, in some cases, spilling of content from the labial commissure and interposition of the tongue to help incompetent lip sealing have been observed in adapted swallowing (Bertolini *et al.*, 2003; Peng *et al.*, 2003, 2004).

The method proposed and used in the present study may point towards new modalities to treat atypical deglutition since it increases the possibility of achieving an objective diagnosis for this functional abnormality. Moreover, this methodology may be used in other studies, thereby creating favourable conditions for diagnosing abnormalities of facial bone growth and development resulting from functional deviations, which are harmful to the stomatognathic system. Among these are oral respiration and sucking without nutritive purposes since these present a very close relationship with the functional changes that cause atypical deglutition and they are harmful oral habits.

Conclusions

1. Cephalometric analysis of the H–MP distance revealed a mean difference of approximately 5 mm between the two groups, and the difference was more than 7 mm for H–T distance.
2. Distances of H–MP and H–T based on radiographic measurements were greater in individuals with atypical deglutition than in normal individuals.
3. And there was no correlation between these two parameters.
4. The radiographic position of the hyoid bone may provide useful information that would help in the diagnosis of atypical deglutition in children.

Acknowledgements

Authors wish to thank the Foundation for Coordination of Advancement of University-level Personnel (Fundação Coordenação de Aperfeiçoamento de Pessoal de Nível Superior; CAPES), Brazil, for financial support. Part of doctoral thesis—Discipline of Otorhinolaryngology, School of Medical Sciences, State University of Campinas (Unicamp), Brazil.

References

Bertolini M M, Vilhegas S, Paschoal J R 2003 Cephalometric evaluation in children presenting adapted swallowing during mixed dentition. *International Journal of Orofacial Myology* 29: 29–41

- Bibby R E 1984 The hyoid bone position in mouth breathers and tonguethrusters. *American Journal of Orthodontics* 85: 431–433
- Bibby R E, Preston C B 1981 The hyoid triangle. *American Journal of Orthodontics* 80: 92–97
- Cayley A S, Tindal A P, Sampson W J, Butcher A R 2000 Electropalatographic and cephalometric assessment of myofunctional therapy in open-bite subjects. *Australian Orthodontics Journal* 16: 23–33
- Cheng C F, Peng C L, Chiou H Y, Tsai C Y 2002 Dentofacial morphology and tongue function during swallowing. *American Journal of Orthodontics and Dentofacial Orthopedics* 122: 491–499
- Ferraz M J P C, Nouer D F, Teixeira J R, Berzin F 2007 Cephalometric assessment of the hyoid bone position in oral breathing children. *Brazilian Journal of Otorrhinolaryngology* 73: 47–52
- Galvão C A A N 1983 Hyoid bone's cephalometric positional study in normal and in malocclusion patients. *Revista de Odontologia da UNESP* 12: 143–152
- Graber T M, Rakosi T, Petrovic A G 1985 Dentofacial orthopedics with functional appliances. C.V. Mosby Company, St Louis, pp. 139–160
- Jamielson A, Guillemineault C, Partinem M, Quera-Salva M A 1986 Obstructive sleep apnoeic patients have craniomandibular abnormalities. *Sleep* 9: 469–477
- Kikyo T, Saito M, Ishikawa M 1999 A study comparing ultrasound images of tongue movements between open bite children and normal children in the early mixed dentition period. *Journal of Medical Dental Science* 46: 127–137
- Malkoc S, Usumez S, Nur M, Donaghy C E 2005 Reproducibility of airway dimensions and tongue and hyoid positions on lateral cephalograms. *American Journal of Orthodontics and Dentofacial Orthopedics* 128: 513–516
- Mays K A, Palmer J B, Kuhlemeir K V 2009 Influence of craniofacial morphology on hyoid movement: a preliminary correlational study. *Dysphagia* 24: 71–76
- Muto T, Kanazawa M 1994 Positional change of the hyoid bone at maximal mouth opening. *Oral Surgery, Oral Medicine, and Oral Pathology* 77: 451–455
- Ovsenik M, Farcnik F M, Korpar M, Verdenik I 2007 Follow-up study of functional and morphological malocclusion trait changes from 3 to 12 years of age. *European Journal of Orthodontics* 29: 523–529
- Pae E K, Quas C, Quas J, Garrettd N 2008 Can facial type be used to predict changes in hyoid bone position with age? A perspective based on longitudinal data. *American Journal of Orthodontics and Dentofacial Orthopedics* 134: 792–797
- Peng C L, Jost-Brinkmann P G, Yoshida N, Chou H H, Lin C T 2004 Comparison of tongue functions between mature and tongue-thrust swallowing—an ultrasound investigation. *American Journal of Orthodontics and Dentofacial Orthopedics* 125: 562–570
- Peng C L, Jost-Brinkmann P G, Yoshida N, Miethke R R, Lin C T 2003 Differential diagnosis between infantile and mature swallowing with ultrasonography. *European Journal of Orthodontics* 25: 451–456
- Riley R, Guillemineault C, Herran J, Powell N 1983 Cephalometric analyses and flow-volume loops in obstructive sleep apnoea patients. *Sleep* 6: 303–311
- Rocabado S M 1983 Biomechanical relationship of the cranial cervical and hyoid regions. *Journal of Craniofacial Practice* 3: 61–66
- Sheng C M, Linb L H, Suc Y, Tsaid H H 2009 Developmental changes in pharyngeal airway depth and hyoid bone position from childhood to young adulthood. *Angle Orthodontist* 79: 484–490
- Stepovich M L 1965 A cephalometric positional study of the hyoid bone. *American Journal of Orthodontics* 51: 882–890
- Tsai H H, Hob C Y, Leec P L, Tand C T 2007 Cephalometric analysis of nonobese snorers either with or without obstructive sleep apnea syndrome. *Angle Orthodontist* 77: 1054–1061